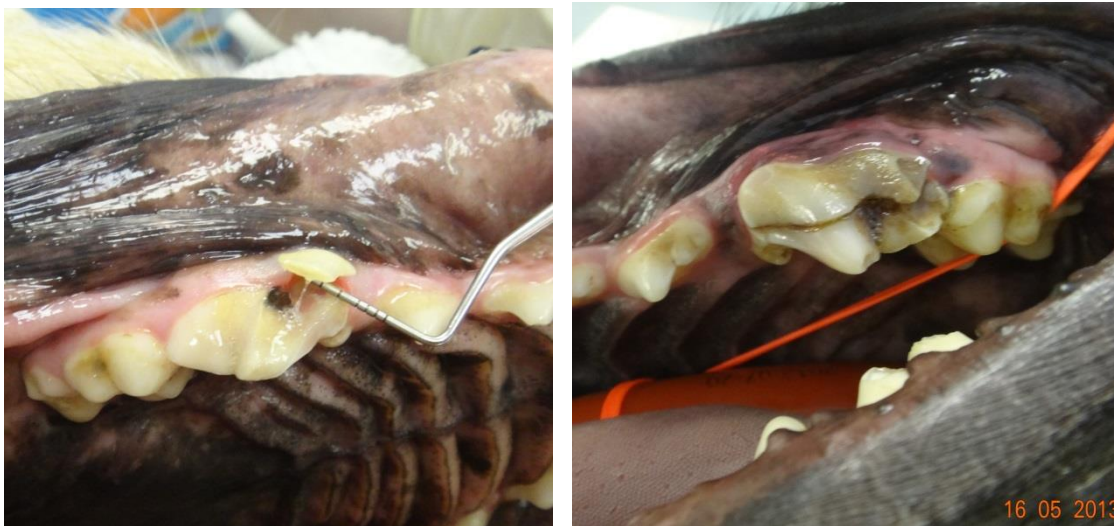

## Safety of Toys for Dogs from a Dental Perspective

Owners ask us frequently what sort of dental toy is safe for their dogs. This conversation often takes place after their pet has been treated for a fractured tooth or some other dental injury. Traumatic damage to teeth is the most common reason, by far, for a dog being referred to us for treatment.

Dogs vary widely in head shape and size. They have a classic carnivore dentition which means the back teeth (carnassials) are scissor blades designed to cut their prey into strips to swallow while the front teeth (canines and incisors) are mainly for catching prey, defensive/offensive behaviour and fine nibbling, as in grooming. Most dogs have a long and narrow head shape and their prey in the wild would be rabbits, squirrels and the like. For the domestic dog this size and texture of food would be normal.

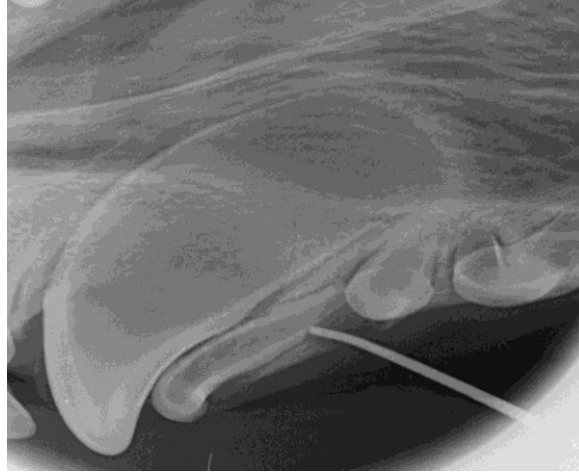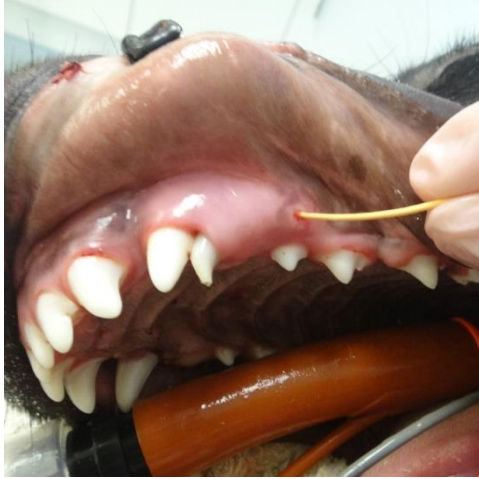
The scissor action of the back carnassial teeth requires the teeth to come together very closely. These teeth also have sharp cusps which make them very vulnerable to objects placed between them that are harder than the tooth itself. Once the powerful closing forces of the jaw, sometimes up to a tonne on a snap bite, are factored into the equation it becomes obvious that excessively hard objects are likely to be a problem. Crushing of bones or other objects larger than normal prey is very risky for domestic dogs. In the past the main culprit was bones from the butcher. Large knuckle bones were preferred because the risk of choking or stomach damage from splinters was less. The problem of the large bone size was mainly tooth fracture in the carnassial area. Butcher's bones also were not particularly hygienic around the house. Dogs did enjoy them but that certainly did not mean that they came without problems



**Two fractured upper carnassial teeth from chewing antlers. Both show typical slab fractures and pulp exposure. Treatment is a root canal filling or a difficult surgical extraction.**

More recently toys have been introduced to simulate chewing of bones. These can be bones that have been cleaned up in some way or other objects, such as antlers, bull horns or very hard nylon bones. None of these items we would consider safe and all of them result in fractured teeth that are referred to us for treatment. The list also includes large sticks and dry hide chews – especially if

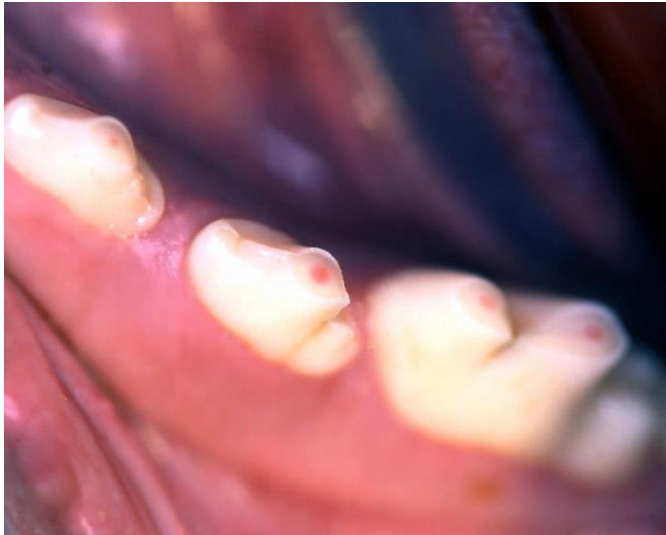
knotted. Sticks cause tooth fracture but pieces of wood can also become trapped between teeth and sometimes across the roof of the mouth. The worst stick injury comes from a dog running onto a thrown stick end-on, severely damaging the mouth and throat. The fragments of wood and bark embedded in the soft tissues can only be found with lots of luck or an MRI scan.



**9 month old pup with fractured upper persistent deciduous canine from hard nylon chew. Rubber cone in tracking sinus shows source of pus at the root apex of the deciduous tooth in radiograph.**

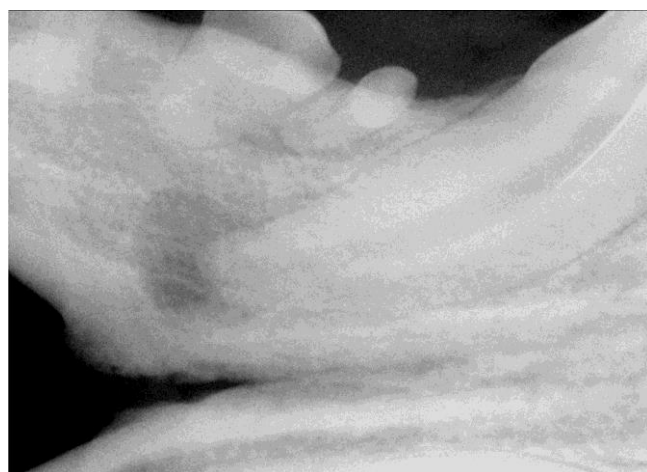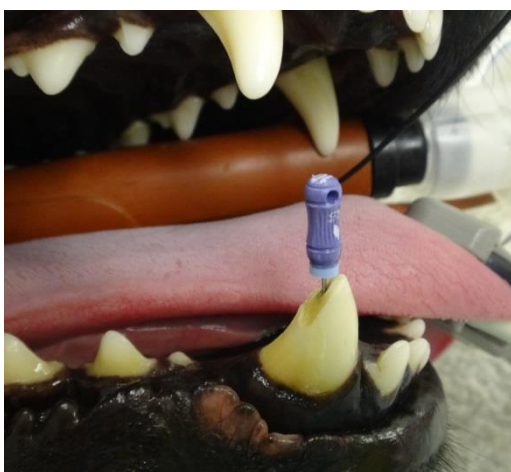
What is the safest item to give your dog to chew and also allow for enrichment of normal behaviour? Our advice is simply not to give your dog anything to chew that you cannot dent with a thumbnail or would not bend or break in the mouth when in contact with teeth. In some large pet superstores it can be hard to find any item that is safe using these criteria! Rawhide chews are often very hard when bought but once softened with warm water are acceptable. Silicon rubber sticks (Safestix™) are also safe in the mouth.

The second main problem with toys for the mouth is dental abrasion. The humble tennis ball is by far the worst offender as the furry surface carries sand and grit – often wet. If the dog holds the tennis ball in the mouth and rolls it around for 20 minutes or so two or three times daily, it's not long before the teeth can be worn down to the gum line. Think of them as coarse grit sandpaper. A smooth semi-hollow rubber ball is much safer and less likely to cause abrasion to the tooth surface.

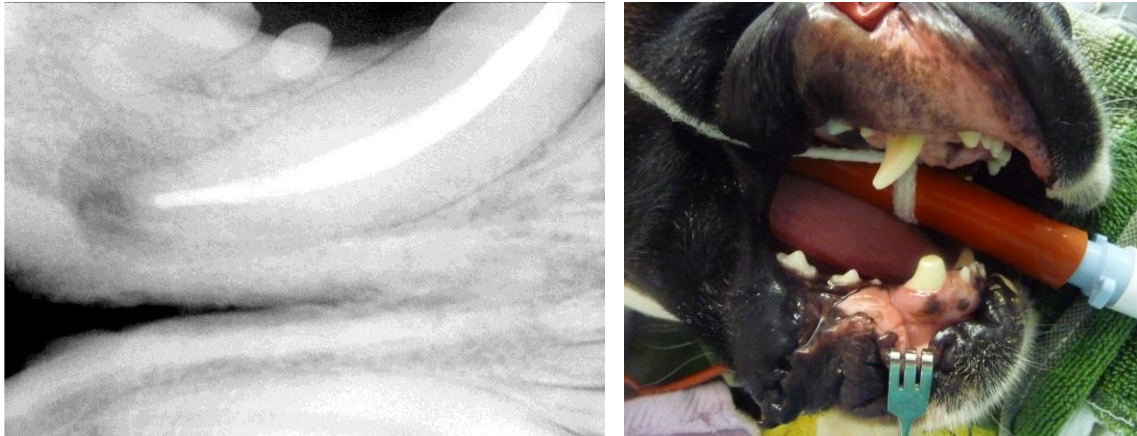


**Tooth abrasion: teeth worn down from carrying tennis balls. Now very close to the pulp –see pink spots.**

What is the consequence of hard chew toy fracture or tennis ball abrasion? The hard toys are most likely to cause tooth fracture. If a fractured tooth has pulp exposure (a complicated crown fracture) the pulp will become inflamed and infected. This is pulpitis or, put more simply, toothache. If the tooth is not treated by either removing it altogether, or removing the pulp with a root canal procedure, the next stage will be leakage of toxins from the pulp to the bone surrounding the root. This so-called “root abscess” is very painful and debilitating. Often we are told that a dog with a fractured tooth is “not in pain”. How can we know this? The fact is the dog is not exhibiting pain and that is not the same thing. They don't drive, read, watch TV or go to work. They suffer in silence mostly.

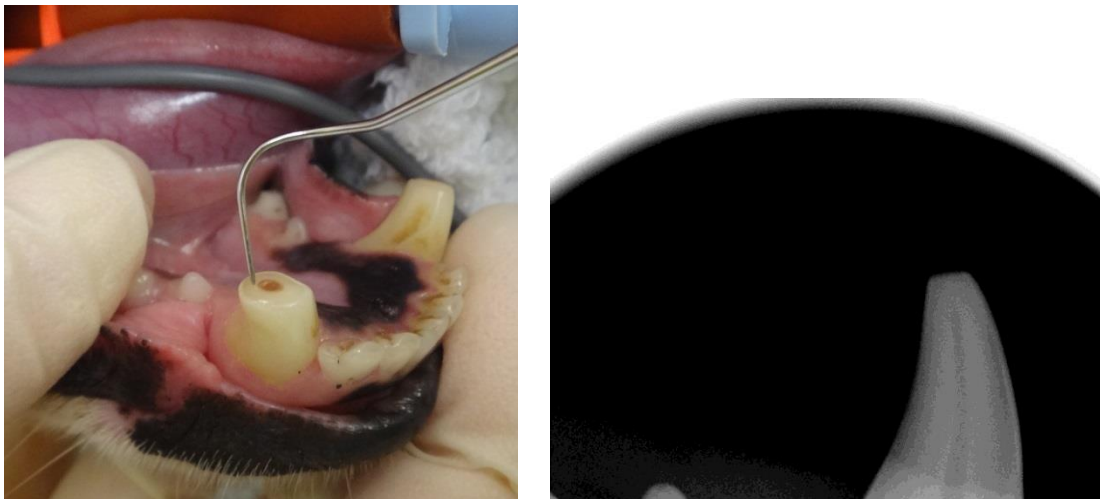


**Fractured lower canine with root canal file in open pulp access. Radiograph shows large dark area around root. This is inflamed and infected bone. This will be very painful but the dog appeared "normal" to the owner.**

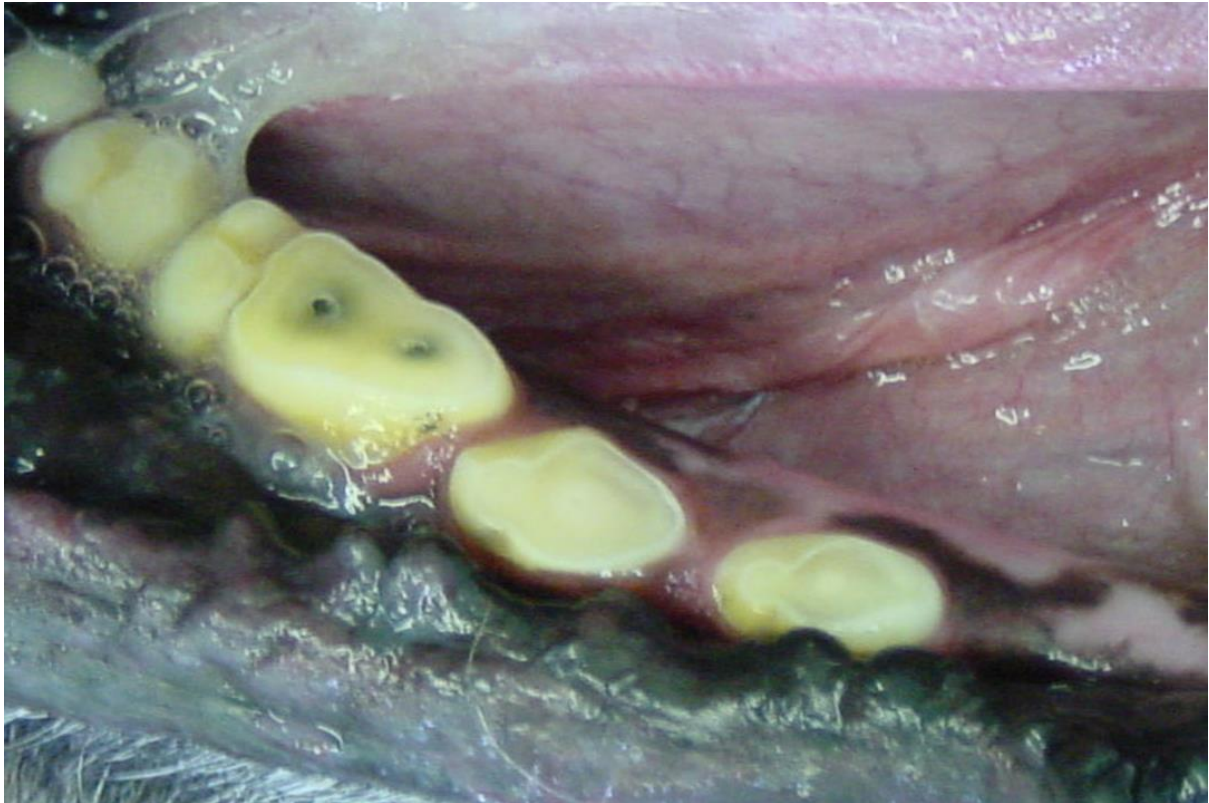

**Radiograph of the same tooth root filled with rubber and cement after dead pulp removed. Tooth smoothed off to prevent damage to tongue from the jagged surface**

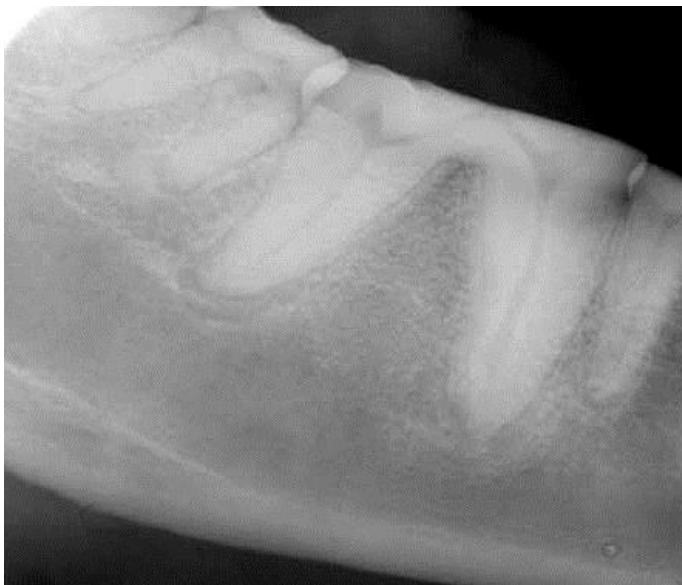Tennis ball abrasion occurs over a longer time. It is not a single catastrophic event but a long period of low grade, abrasion damage. As the teeth wear down it is possible for the pulp of the tooth to attempt an internal repair with tertiary dentine. This can protect the tooth from pulp exposure but some teeth may wear to the gum line without opening the pulp whilst in others the pulp will open resulting in the same consequences as the fractured tooth. Once the pulp is open, or close to exposure, the same rules of treatment apply – remove the tooth or remove the pulp in a root canal procedure.



**Tooth abrasion canine tooth with no pulp exposure yet. Tertiary dentine shows as brown spot but probe does not penetrate to pulp. Radiograph shows proximity of pulp to worn surface. Currently this tooth requires no treatment - as long as further abrasion ceases.**



**Tooth abrasion from long term tennis ball use. Some teeth worn flat to gumline with no pulp exposure. The carnassial has overt pulp exposure over both roots. See radiograph below.**



**Radiograph teeth worn to gum line. Abnormal changes in bone round both roots lower carnassial**

What is really safe for your dog? We discussed the general rule that being unable to make an impression in the object with your thumbnail being a good guide. Think how your own teeth might be damaged with the object you are about to give your dog. Humans don't generally bite very hard

objects for a good reason. We know the consequences of our action will not be pleasant. Dogs don't often think before they bite down.

Lastly it makes sense to treat claims made on product packaging with some scepticism. Claims that hard chews are "good for puppy teeth" and that bones and the like "naturally clean teeth" have no foundation in fact and are simply there to sell. If any manufacturer of hard chews has ever tested their wares properly and scientifically to substantiate the claims they make we have yet to see the study. Caveat emptor - cura dentus.



**Safestix is use**

**Norman Johnston**  
**RCVS, European & American Specialist in Veterinary Dentistry**  
**DentalVets, North Berwick.**